



**MELBOURNE  
EQUINE**  
VETERINARY GROUP

Equine Veterinary Surgeons  
130 Kambrook Road, Caulfield East, Vic. 3145  
PO Box 523, Carnegie, Vic. 3163  
ABN: 76 432 417 462 A.C.N: 092 338 317  
Phone: (03) 9572 0666 Fax: (03) 9572 0199  
Email: [mevg@mevg.com.au](mailto:mevg@mevg.com.au)  
[www.mevg.com.au](http://www.mevg.com.au)

Date: 1/5/17

Horse name: TUCANO

Report prepared for: Ciaron Maher racing

#### Vet report

The above horse was examined to investigate reports of poor performance and lameness. At a trot the horse appeared to have a choppy action but resented fetlock flexion and became 3 out of 5 lame on the right fore limb after fetlock flexion.

The joint was moderately effused with a soft tissue swelling on the dorsal lateral aspect of the joint.

The handler reported that heat has been regularly detected in the right fore fetlock.

Radiographs of the fetlock joint were obtained and showed some subtle signs of underlying pathology.

Firstly a notch on the dorsal aspect of the distal cannon bone was identified which may indicate that the soft tissue swelling described above may be hypertrophy of the villonodular pad. (Red arrow).

The second and more worrying radiographic finding was the white appearance of the distal cannon bone (sclerosis - Blue arrow).

This finding can be an indication that the bone is not adapting to the stresses put on it and it is becoming brittle.

Further radiographic views revealed a radiolucent area on the sagittal ridge of the distal cannon bone (yellow arrow), which may indicate a cyst like lesion or sub chondral bone necrosis.

When put together with the history and the severity of the lameness, my main concern is that this bone is not coping with the stress of training and may be showing warning signs of pre-fracture.

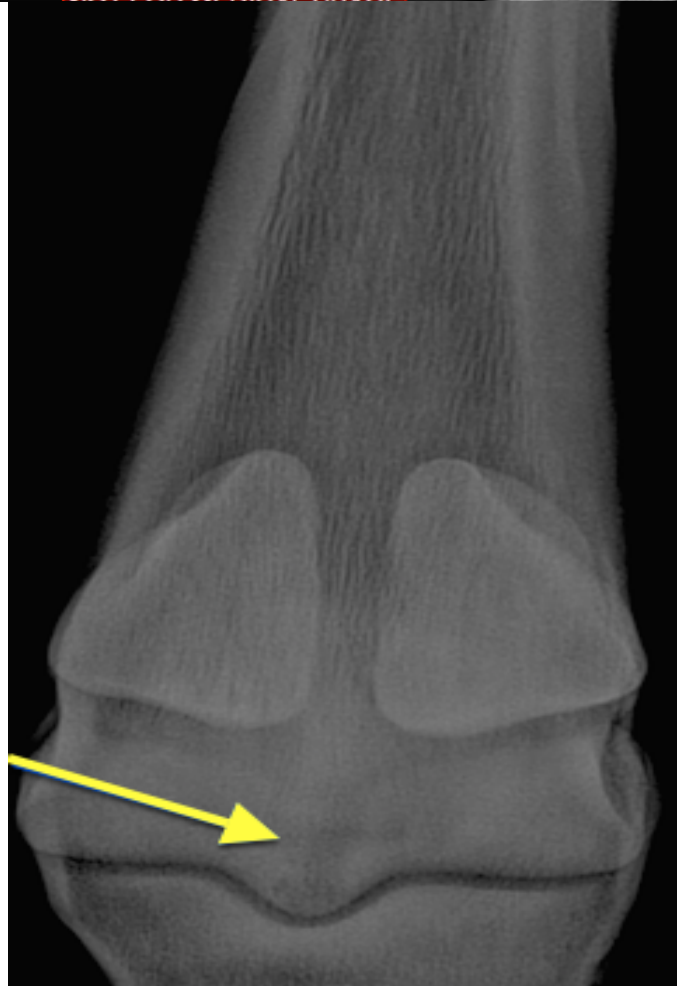
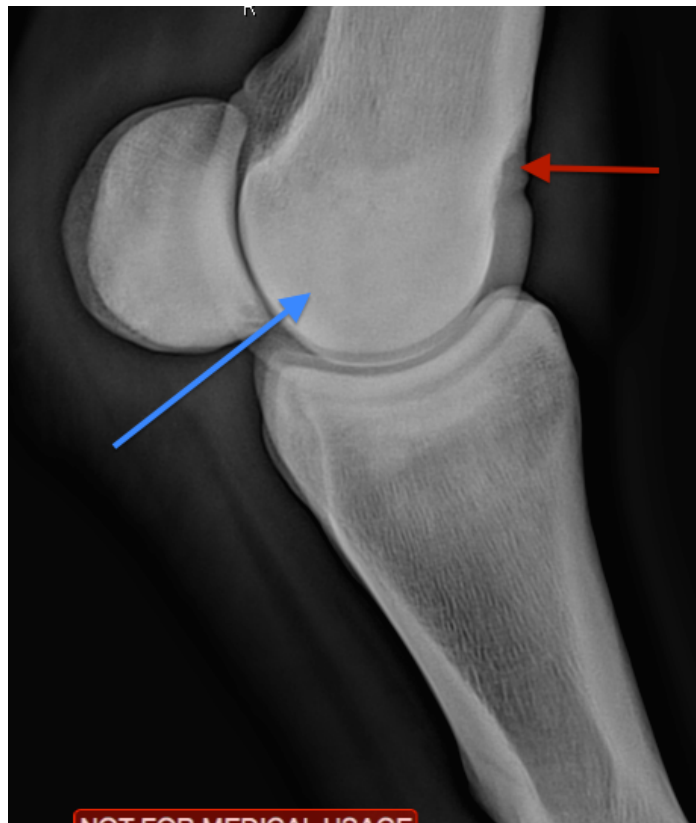
If you are happy to spend the money, further diagnostics can be undertaken to obtain a definitive diagnosis and include nerve blocks, ultrasound, scintigraphy and diagnostic arthroscopy. Having said that I would still advise that this horse receive a long spell due to the severity of the lameness and considering the age of the horse, retirement from racing may be considered as an option.

If you have any questions, please do not hesitate to contact us.

Regards,

John William Russell BVMS MRCVS MANZCVS (Equine surgery)

This report and findings contained herein are solely for the addressee stated above and may not be relied upon or used by any other person entity without the express written consent from Melbourne Equine Veterinary Group. The interpretation of diagnostic images and findings may vary with examiner, method of examination and the horses changing condition. This is a report of the undersigned's findings on the date stated. This report is limited to the findings contained herein and no other findings should be inferred beyond those expressly set forth herein. This report does not express a warranty or guarantee of any kind by Melbourne Equine Veterinary Group.



This report and findings contained herein are solely for the addressee stated above and may not be relied upon or used by any other person entity without the express written consent from Melbourne Equine Veterinary Group. The interpretation of diagnostic images and findings may vary with examiner, method of examination and the horses changing condition. This is a report of the undersigned's findings on the date stated. This report is limited to the findings contained herein and no other findings should be inferred beyond those expressly set forth herein. This report does not express a warranty or guarantee of any kind by Melbourne Equine Veterinary Group.